



ALTERATION IN KIDNEY BIOMARKERS AFTER TREATMENT OF SODIUM FLUORIDE AND AMELIORATION WITH *TAMARINDUS INDICA* AND VITAMIN D IN *RATTUS NORVEGICUS*

Shalini Yadav^{1&4}, Prem Sagar¹, Shekhar Biswas², Vishan Kumar³ and P. K. Singh⁴

¹Department of Zoology, Government PG College, Jalesar, Affiliated to RMPSU Aligarh, Uttar Pradesh, India

²Department of Zoology, Agra College, Agra Affiliated to Dr. Bhimrao Ambedkar University, Agra, Uttar Pradesh, India

³Department of Zoology, NREC College, Khurja, Affiliated to Meerut University Meerut, Uttar Pradesh, India

⁴Department of Zoology, SLS Khandari, Dr. Bhimrao Ambedkar University, Agra, Uttar Pradesh, India

Email-shalini.yadav211092@gmail.com

www.doi.org/10.59436/jsiane.com/archives3/4/113

Abstract

Fluoride is one of the trace elements with very active chemical properties. Fluoride, the element with the greatest electronegativity, is a significant industrial and ambient contaminant. Along with a number of other elements, it generates ionized fluorides. Food, drink water, toothpastes, fluoride additives, professionally administered fluoride gel and emissions from companies using hydrofluoric acid and fluoride-containing salt are all sources of fluoride. The dangerous illness known as fluorosis can be brought on by prolonged and high exposure to inorganic fluoride. Sodium fluoride is frequently used as an essential part of dental decay prevention. After 7, 15, 30, 45 and 60 days of exposure to sodium fluoride in the treated group as compared to the control group, *Rattus norvegicus* showed substantial increases in kidney biomarkers Urea, Creatinine, Uric acid and Blood Urea Nitrogen (BUN). The current study shows that different kidney biomarkers are adversely affected by Sodium fluoride while *Tamarindus indica* and Vitamin D ameliorate the effect of sodium fluoride.

Keywords: Sodium fluoride, *Rattus norvegicus*, *Tamarindus indica*

Received 07.09.2023

Revised 11.10.2023

Accepted 23.12.2023

Introduction

One of the trace elements with very active chemical characteristics is fluoride. The most electronegative element, fluoride, is a major industrial and natural environmental pollutant. It produces ionized fluorides with several other elements. Fluoride can be found in food, drink water, toothpastes, fluoride additives, professional fluoride gel administration and emissions from industries that use hydrofluoric acid and fluoride containing salt. Prolonged and extensive exposure to inorganic fluoride can result in the serious health disease known as fluorosis. Sodium fluoride is widely utilized as a crucial component in the fight against tooth decay, and studies have shown that it can effectively prevent dental caries when present in low concentrations in products used for oral hygiene (Clarkson *et al.*, 2011). The distribution of fluoride following oral exposure to drinking water, as well as its related effects on biochemical and antioxidant indicators and histology in the liver, kidney and heart of male Wistar rats, are studied by (Sharma *et al.*, 2023). According to pharmacological studies, extracts from *Tamarindus indica* have antibacterial, antifungal, hypoglycemic, cholestolemic, cytotoxic, anti-inflammatory, gastrointestinal and hypolipemic properties (Bhadoria *et al.*, 2011 and Librandi *et al.*, 2007). Numerous studies have also discovered the antioxidant actives in *Tamarindus indica* (Parvez *et al.*, 2003). Essential organ that is in charge of numerous functions is the kidney. They keep the body's electrolyte levels stable, eliminate waste products and control

blood pressure. The kidney, the body's biggest excretory organ, is essential for filtering body waste. Renal tubes are crucial to the elimination of waste from the kidney, which excretes between 50 and 80 percent of sodium fluoride. On the other hand, renal disorders such as polycystic kidney disease may be brought on by the chronic fluoride exposure-induced malfunction of renal tissue.

Material and Methods

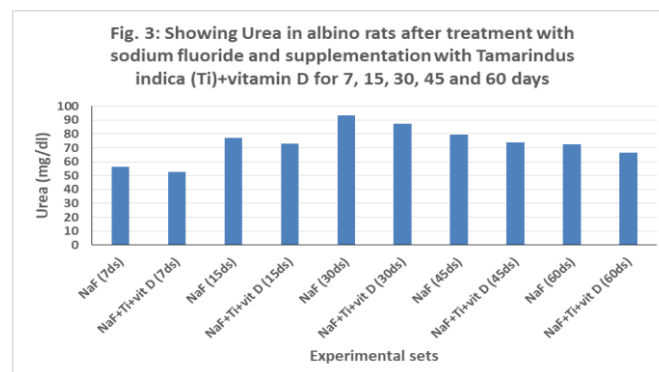
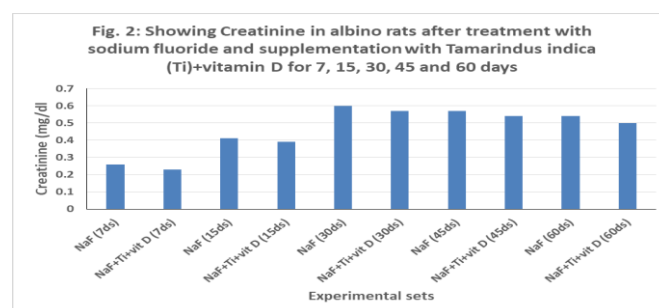
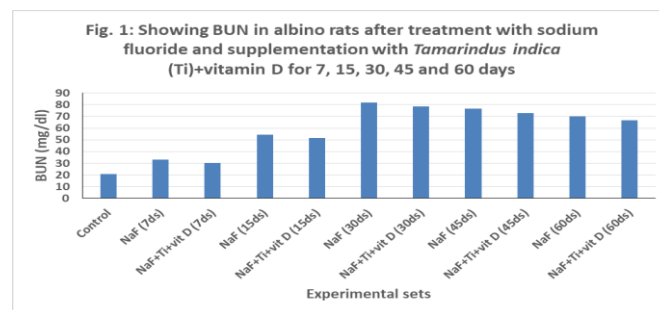
For this experiment, we utilised male albino rats (*Rattus norvegicus*) of the wistar strain, which were raised in the Animal house of Zoology Department, School of Life Sciences, Khandari Campus, Dr. Bhimrao Ambedkar, University, Agra. Their weight ranged from 120±25g. The albino rats were kept under tightly regulated conditions, including a temperature of 25±20°C, humidity of 65±10%, and a correct circadian rhythm, in polypropylene cages that measured 45x25x15cm. As per the procedure, the acclimatized rats were split into several groups and kept in separate cages for 7, 15, 30, 45 and 60 days of the experiment. One set was treated with sodium fluoride, while the other sets were supplemented with a combination of sodium fluoride, *Tamarindus indica* and vitamin D. All they needed to be healthy was a regular diet of Goldmohar brand feed and unlimited water. Albino rats were administered sodium fluoride (NaF) as the fluoride. Administer 10 milligrammes of sodium per kilogramme of body weight. The *Tamarindus indica* fruits were purchased at the neighbourhood market. The Khandari Campus, Agra-based

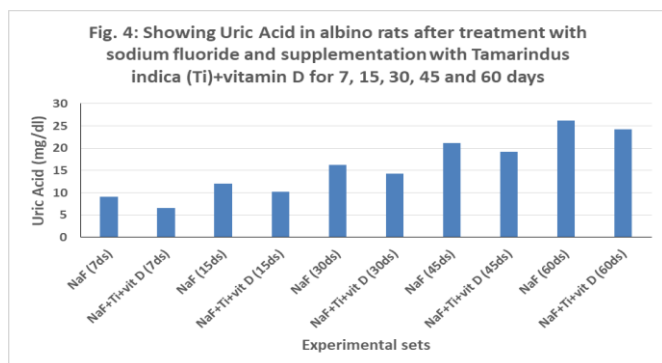
Department of Botany of the School of Life Sciences performed the taxonomic identification on all of the items. We mimicked the indigenous process by extracting the *Tamarindus indica* pulp with hot water to get an aqueous extract. *Tamarindus indica* contains 52% of the recommended daily intake (RDI) of vitamin C; the dosage used for therapeutic purposes was 10 grammes per kilogramme of body weight. The vitamin D powder was procured from a medical store and the dose given was 5mg/kg body weight. All treatments were given orally using a syringe and a bent tip canula. The doses were given for 7, 15, 30, 45 and 60 days respectively. The albino rats of all the groups were sacrificed under light anesthesia. The biochemical parameters were estimated through standard procedures and protocols viz. BUN in the serum was estimated by the method of Talke and Schubert (1965). Using the alkaline picrate approach, which was detailed by Toro and Ackermann (1975), the serum creatinine level was determined. The GLDH-Urease technique, as outlined by Young (1990), was used to measure serum urea. Tietz (1995) described the Uricase Enzymatic technique, which was developed by Anamol Laboratories, for the purpose of estimating uric acid.

Results and Discussion

In the present study significant alteration in kidney profile parameters viz. BUN, creatinine, urea, and uric acid has been observed after sodium fluoride intoxication for 7, 15, 30, 45 and 60 days respectively and modulation has also been observed with supplementation of extract of *Tamarindus indica* and vitamin D. However, after administration of *Tamarindus indica* with sodium fluoride, the toxic effect generated by free radicals is minimized and protective effects reveals the antioxidative ability of extract against sodium fluoride toxicity. *Tamarindus indica* extract has major amount of ascorbic acid which is well absorbed from the gastrointestinal tract. Ascorbic acid is absorbed in the body by both active transport and simple diffusion. Sodium fluoride toxicity may also be lessened by adopting an antioxidant rich diet, such as that of *Tamarindus indica*. Present results and findings are also supported by histopathological changes in renal tissue from oxidative stress caused by varying fluoride concentrations were noted by (Luo *et al.*, 2017). Renal function parameters show elevated contents of serum creatinine (Cr), serum uric acid (UA), blood urea nitrogen (BUN), and elevated levels of urinary N-acetyl-b-Dglucosaminidase (NAG), renal lactate dehydrogenase (LDH) and minimized activities of sodium-potassium adenosine triphosphatase (Na^+/K^+ -ATPase) and acid phosphatase (ACP) in the cells of the kidney. According to (AlDaihan *et al.*, 2019) bee pollen was shown to protect rats from the hepatonephrotoxicity and serum electrolyte abnormalities caused by sodium fluoride. The elevated serum magnesium levels we observed in NaF-treated rats are indicative of impaired kidney function since magnesium is eliminated exclusively in urine. Analysis of serum K^+ and Na^+ levels revealed a considerable reduction in the latter, which may suggest renal dysfunction due to decreased tubular reabsorption and osmotic disequilibrium between the luminal fluid and the medullary interstitial fluid, both of which may hinder dilution. A little rise in K^+ concentration due to NaF may be an indication of impaired renal function and damage to membrane channels. Chloride ion concentrations were lower than the baseline but not statistically significant. According to (Yildirim *et al.*, 2018)

shows study of the long-term impact of 7, 12-dimethylbenz[a]anthracene and sodium fluoride on rat blood parameters, kidney and heart histopathology. Excessive formation of oxygen free radicals, enhanced lipid peroxidation, increased AST, ALT, LDH, CK, CK-MB, creatinine and cardiac troponin I values, decreased K, Na, Cl and urea levels, and inhibition of antioxidative enzymes were all seen in the current investigation of chronic fluorosis+DMBA toxicity. (Dharmaratne, 2018) summarized research into the connection between high fluoride intake and chronic kidney disease. This review indicates that there is a direct association between CKD and the ingestion of high levels of fluoride. (Malina *et al.*, 2019) studied the relationship between adolescent fluoride exposure and kidney and liver function. Rise in serum uric acid and decrease in blood urea nitrogen and glomerular filtration rate estimation. An increase in water fluoride was found as associated with decreased blood urea nitrogen content. Abdel-Baky and Abdel-Rahman (2020) reported garlic, *Allium sativum* was tested for its heart protective properties in rats given sodium fluoride. Serum creatinine kinase, creatine kinase, lactate dehydrogenase (LDH), aspartate aminotransferase (AST), alanine aminotransferase (ALT) and cardiac troponin I were all significantly increased by NaF. (Caglayan *et al.*, 2021) to see how well they protect the liver and kidney from sodium fluoride-induced damage. Increases in blood urea and creatinine, as well as changes in the levels of liver enzymes revealed that NaF caused hepatic and renal damage.





References

- Abdel-Baky and Abdel-Rahman (2020) Cardioprotective effects of the garlic (*Allium sativum*) in sodium fluoride-treated rats. *J. Bas. Appl. Zool.*, **81**(7): 1-7.
- Al-Daihan S. and Bhat, R. (2019) Protective effect of bee pollen against sodium fluoride induced hepatonephrotoxicity and serum electrolyte changes in rats. *Fluor.*, **52**: 9-17.
- Caglayan, C., Kandemir, F. M., Darendelioğlu, E., Küçükler, S. and Ayna, A. (2021) Hesperidin protects liver and kidney against sodium fluoride-induced toxicity through anti-apoptotic and anti-autophagic mechanisms. *Life Sci.*, **281**:119730.
- Clarkson, J.J., Kevin, H., David, B. and Richardson, L.M. (2011) International collaborative research on Flouride. *J. Dent. Res.*, **79**(4): 893-990.
- Dharmaratne, R.W. (2018) Exploring the role of excess fluoride in chronic kidney disease: A review. *Hum. Exp. Toxicol.*, **38**(3): 269-279.
- Landi, A. P., Chrysóstomo, T. N., Azzolini, A. E., Recchia, C. G., Uyemura, S. A. and de Assis-Pandochi, A. I. (2007) Effect of the extract of the tamarind (*Tamarindus indica*) fruit on the complement system: studies in vitro and in hamsters submitted to a cholesterol-enriched diet. *Food Chem. Toxicol.*, **45**(8): 1487-1495.
- Luo, Q., Cui, H., Deng, H., Kuang, P., Liu, H., Lu, Y., Fang, J., Zuo, Z., Deng, J., Li, Y., Wang, X. and Zhao, L. (2017) Histopathological findings of renal tissue induced by oxidative stress due to different concentrations of fluoride. *Oncotarget.*, **8**(31): 50430-50446.
- Malin, A. J., Lesseur, C., Busgang, S. A., Curtin, P., Wright, R.O. and Sanders, A. P. (2019) Fluoride exposure and kidney and liver function among adolescents in the United States: NHANES, 2013-2016. *Environ. Int.*, **132**(105012): 1-9.
- Parvez, S., Mohammad, P., Eiji, N., Hiroshi, G. and Yoshiharu, F. (2003). *Tamarindus indica* L. leaf is a source of allelopathic substance. *Plant Grow. Regul.*, **40**(2): 107-115.
- Sharma, P., Verma, P. K., Sood, S., Singh, M. and Verma, D. (2023) Impact of Chronic Sodium Fluoride Toxicity on Antioxidant Capacity, Biochemical Parameters, and Histomorphology in Cardiac, Hepatic, and Renal Tissues of Wistar Rats. *Biol. Trace Elem. Res.*, **201**(1): 229-241.
- Talke, H. and Schubert, G. E. (1965) Klinische Wochenschrift, **43**: 174.
- Teitz, N. W. (1995) ed. Clinical guide to laboratory tests 3rd ed. *Philadelphia, Pa: WB Saunders company*, 624-626.
- Toro G, Ackermann PG. (1975) Practical clinical chemistry. Boston, MA: Little, Brown.
- Yildirim, S., Ekin, S., Huyut, Z., Oto, G., Comba, A., Uyar and Cinar, D. A. (2018) Effect of chronic exposure to sodium fluoride and 7, 12-dimethylbenz [a] anthracene on some blood parameters and hepatic, renal, and cardiac histopathology in rats. *Fluor.*, **51**(3): 278-290.
- Young, D. S., Pestaner, L. C. and Gibberman, V. (1975) Effects of drugs on clinical laboratory tests. *Clin Chem.*, **21**: 371O-73D.

Cite this article:

Shalini Yadav, Prem Sagar, Shekhar Biswas, Vishan Kumar and P. K. Singh, 2023, "Alteration in Kidney Biomarkers after Treatment of Sodium Fluoride and Amelioration with *Tamarindus indica* and Vitamin D in *Rattus norvegicus* " *Journal of Science Innovations and Nature of Earth*, Vol. 3(4), page-34-36
www.doi.org/10.59436/jsiane.com/archives3/4/113